

The Eccentric Posterior Polar Cataract (PPC)t

Harshal Sahare¹, Uttkarsha Thakre², Mahesha S², Kajal Bansal³

¹ Department of Clinical Vitreo-retina, ²Department of Phaco and cataract, ³Department of Ophthalmology, ¹⁻³Sankara Eye Hospital, Shimoga, Karnataka, India.

Abstract

A 54-year-old male with limited left-eye vision for six months with no history of trauma. The left eye's slit-lamp examination reveals highly defined eccentric round or oval opacity with an onion-shaped ring in the posterior subcapsular cortex of the crystalline lens, suggesting eccentric posterior polar cataract (PPC) [Fig. a and b]. A posterior polar cataract is comprised of dysplastic lens fibres that accumulate extracellular material and exhibit progressive lens opacity and degenerative changes as they migrate posterior from the lens equator.^{1,2} A discoid posterior polar plaque-like cataract results from these alterations.³ We believe this eccentric PPC is unique and unpublished, to the best of our knowledge.

Key-words: Crystalline lens, Eccentric PPC, Posterior polar cataract.

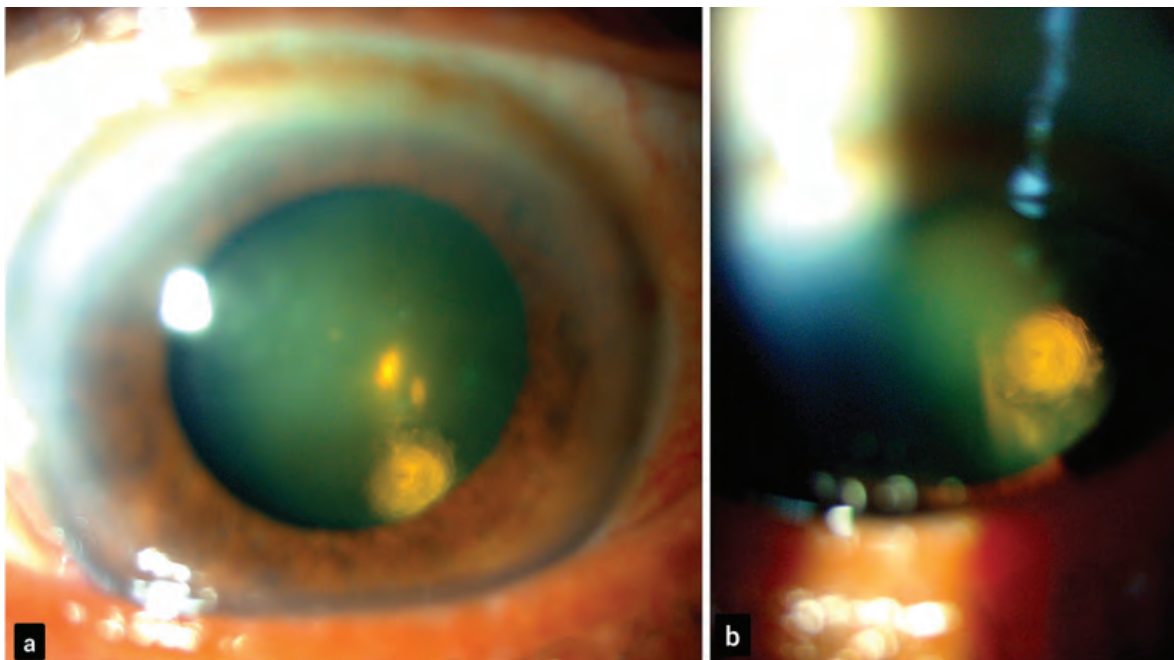


Figure 1: The slit-lamp photograph of the left eye shows sharply defined eccentric round or oval opacity with ringed appearance like an onion shaped in the posterior subcapsular cortex of the crystalline lens suggestive of eccentric posterior polar cataract (PPC) [Fig. a and b].

***Corresponding author:**

Harshal Sahare – Department of Clinical Vitreo-retina, Sankara Eye Hospital, Harakere, Shimoga, Karnataka, India.
E-mail: dr.harshalsahare@gmail.com.

FINANCIAL SUPPORT AND SPONSORSHIP

Nil.

CONFLICTS OF INTEREST

There are no conflicts of interest.

REFERENCES

1. Eshaghian J., Streeten B.W. Human posterior subcapsular cataract; an ultrastructural study of the posteriorly migrating cells. *Arch Ophthalmol.* 1980;98:134-43.
2. Nagata M., Matsuura H., Fujinaga Y. Ultrastructure of posterior subcapsular cataract in the human lens. *Ophthalmic Res.* 1986;18:180-4.
3. Eshajian J. Human posterior subcapsular cataracts. *Trans Ophthalmol Soc UK.* 1982;102:364-68.

How to cite this article: Sahare H, Thakre U, S M, Bansal K., The Eccentric Posterior Polar Cataract (PPC). *Ocul Res J* 2025;2(1): 35-36.

© The Author(s). 2025 Open Access. This article is distributed under the terms of the Creative Commons Attribution 4.0 International License (<https://creativecommons.org/licenses/by-nc/4.0/>), which permits unrestricted use, distribution, and non-commercial reproduction in any medium, provided you give appropriate credit to the original author(s) and the source, provide a link to the Creative Commons license, and indicate if changes were made. The Creative Commons Public Domain Dedication waiver (<http://creativecommons.org/publicdomain/zero/1.0/>) applies to the data made available in this article, unless otherwise stated.